

Adult Variant of Self-healing Cutaneous Mucinosis in a Patient with Epilepsy

Reza Yaghoobi¹, Arezou Bagherzade¹, Maryam Aliabdi¹, Parvin Kheradmand², Afshin Kazerouni¹, Amir Feily³

¹ Department of Dermatology, Ahvaz, Jundishapur University of Medical Sciences, Ahvaz, Iran.

² Department of Pathology, Ahvaz Jundishapur University of Medical Sciences, Ahvaz, Iran.

³ Skin and Stem Cell Research Center, Tehran University of Medical Sciences, Tehran, Iran.

Corresponding Author:

Arezou Bagherzade, MD. Department of Dermatology, Imam Khomeini Hospital, 61335, Ahvaz, Iran.
email: abinmedicine@yahoo.com.

ABSTRAK

Seorang wanita 52 tahun memiliki riwayat periorbital edema dan bibir bengkak selama 3 minggu. Dia mengalami beberapa papula eritematosa padat subkutan dan nodul pada wajah, kulit kepala dan dua plak di punggung atas dan lengan kiri. Lesi ini berkembang pesat. Pasien memiliki riwayat serangan epilepsi sejak kecil. Pemeriksaan umum normal. Terdapat edema ringan pada tangan dan kaki, dan data laboratorium normal. Pemeriksaan histopatologi menunjukkan adanya akumulasi musin berbatas tegas pada lapisan dermis, dengan pulasan alsiyan biru positif. Temuan klinis dan histopatologi diikuti oleh resolusi spontan lesi dalam jangka waktu 4 bulan yang sesuai dengan diagnosis mucinosis kulit yang sembuh sendiri. Kami melaporkan pertama kalinya kasus mucinosis kulit yang berhubungan dengan epilepsi.

Kata kunci: epilepsi, mucinosis, penyembuhan sendiri.

ABSTRACT

A 52-year-old woman was admitted with a 3 weeks history of periorbital edema and lips swelling. She developed several subcutaneous firm erythematous papules and nodules on the face, scalp and two indurated plaques on the upper back and left forearm. These lesions grew rapidly. The patient had a positive history of epileptic seizures since childhood. General examination was normal. There was a mild pitting edema on her hands and feet. Laboratory data were within normal limits. Histopathological examination revealed a well circumscribed accumulation of mucin in the dermis. Alcian blue stain was positive. Clinical and histopathological findings followed by spontaneous resolution of the lesions within a period of 4 months was compatible with diagnosis of self-healing cutaneous mucinosis. Herein we report the first case of self-healing cutaneous mucinosis associated with epilepsy.

Kata kunci: epilepsy, mucinosis, self-healing.

INTRODUCTION

Lichen myxedematosus (LM) is an idiopathic cutaneous mucinosis which is characterized by mucin deposition on histopathologic features and includes two subsets: a generalized papular

form which is called “scleromyxedema” and a localized papular form which is subdivided into 5 subtypes such as 1) discrete papular form, 2) acral persistent, 3) self-healing cutaneous mucinosis, 4) papular mucinosis of infancy, 5)

nodular form.¹ Self-healing cutaneous mucinosis (SHCM) is one of the subtypes of localized papular mucinosis and includes a juvenile and an adult type that represent a mucinosis without paraproteinemia and thyroid dysfunction, the adult type is a very rare entity.² SHCM is characterized by early age of onset and selective distribution of the lesions (in the form of papules, nodules and plaques), also on the area of scalp, face, neck, abdomen, thighs and periarticular regions. All of the lesions resolve after few weeks to few months (spontaneously).^{1,2} We report a case of self-healing cutaneous mucinosis in an adult with history of epilepsy.

CASE ILLUSTRATION

A 52-year-old woman visited emergency department having 3-week history of periorbital edema and lip swelling, low grade fever and aggressive skin lesions (**Figure 1**). She was referred to the department of dermatology for further evaluation with initial diagnosis of angioedema. She received oral anti histamine and low dose oral corticosteroid by general physician in the emergency department and supervised by resident of dermatology patient did not respond to the mentioned therapy. Past medical history revealed a history of epileptic seizures since childhood. She was on treatment by sodium valproate and last episode of seizure was two months earlier.

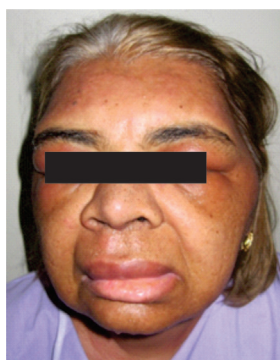

Figure 1. Severe bilateral erythematous periorbital edema with lips swelling

On examination the patient appeared debilitated and febrile (37.7°C oral), with normal vital signs. Cutaneous examination revealed multiform lesions in the subcutan showing

erythematous, firm non tender papules and nodules, ranging from 0.5 to 2 cm diameter, on the face, scalp, retro-auricular, upper back and the left forearm with mildly pruritic sensation (**Figure 2**). There were two erythematous indurated plaques on the left forearm and upper back and nape of the neck there were indurated erythema plaques (**Figure 3**). Other physical examination was unremarkable except for mild pitting edema which was noticeable both on her hands and feet.

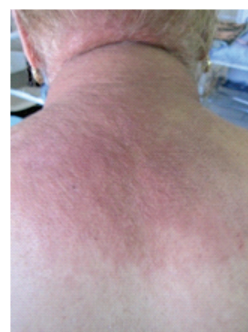

Figure 2. An indurated erythematous plaque affecting upper back and nape of the neck

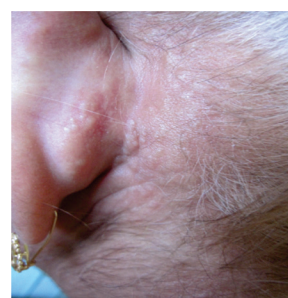


Figure 3. Several small subcutaneous skin color nodules in the retro auricular area

Laboratory work including complete blood cell count, C reactive protein, (erythrocyte sedimentation rate), liver function tests, thyroid function tests, serum creatinine, serum electrolytes and urinalysis, serum electrophoresis were within normal limits except leukocytosis (15000 mm³) during the first day. Bench-Jones proteinuria was not seen. Immunologic investigations included anti nuclear antibodies, anti ds DNA, rheumatoid factor, anti -Sm and complement assay, all were within normal limits. Abdominal ultra sounography, Abdominal CT SCAN without contrast and chest X-ray were normal.

Histopathology examination was performed. The patient was under treatment of low dose steroid when three excisional biopsies of fascia were taken and, steroid was discontinued after confirmation of diagnosis. Hematoxylin and eosin stained sections showed a normal epidermis. Mid and reticular dermis appeared edematous and showed numerous clear spaces between collagen bundles due to mucin deposition. Alcian blue staining at PH=2.5 revealed abnormal blue materials due to mucin deposition in mid to reticular dermis. There was a mild increase in number of fibroblast-like cells between collagen bundles. In some sections mucin deposition extended to subcutaneous tissue along with septa (**Figure 4 and 5**).

The patient was discharged from hospital and was followed every 2 weeks. At each visit the lesions were observed to regress in size. After 4-month follow-up without any specific treatment, all lesions had resolved without any remarks, included periorbital edema and edema on both extremities. Indurated plaques were improved with a mild post inflammatory hyperpigmentation without any scarring (**Figure 6**).

According to the clinical features of skin lesions, association of periorbital edema and histopathological findings and due to spontaneous clearance of skin lesions during a follow up “period of 4-month” diagnosis of self-healing cutaneous mucinosis was established for the patient.

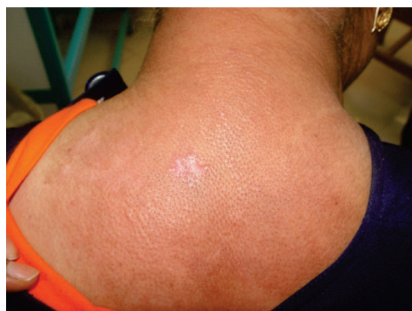


Figure 4. Complete resolution of indurated erythematous plaque on the upper back and nap of the neck except post inflammatory hyperpigmentation.

DISCUSSION

LM is an idiopathic cutaneous mucinosis which was first described by Montgomery and Underwood in 1953.³ There is a classification

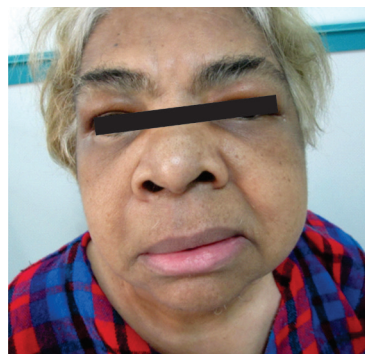

Figure 5. About 4 month after presentation complete resolution of peri orbital and lip swelling

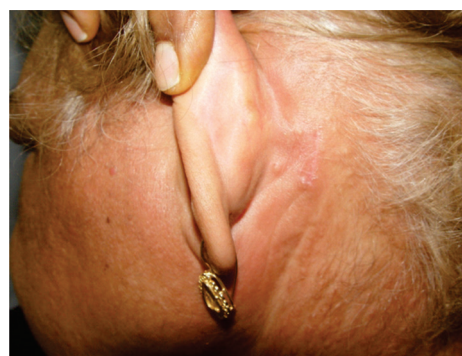

Figure 6. Significant resolution of skin color nodules in the retro auricular area.

of LM in the literature: a generalized papular or sclerodermoid form (called scleromyxedema) and a localized papular form.¹

The localized form of LM divided into 5 subtypes: (1) a discrete papular form which can involve any site, (2) acral persistent papular mucinosis, (3) self-healing papular mucinosis (included juvenile and adult types), (4) papular mucinosis of infancy, a pediatric variant of the discrete form or of acral persistent papular mucinosis, (5) nodular form.

There is a third group of LM that does not have the criteria for either scleromyxedema or the localized form called atypical group.¹

SHCM initially described in children with ages 13 months to 15-year.^{4,5} However, the same disorder was subsequently observed in just a few adults.⁶ To the best of our knowledge, only 6 cases of adult self-healing cutaneous papular mucinosis had been reported in the English literature until 2012 which is listed in **Table 1**.⁷ Our patient was a classical example of an adult variant of self-healing cutaneous mucinosis.

SHCM is characterized by the following clinical presentations: 1) an acute eruption of multiple papules, sometimes coalescing into linear infiltrated plaques on the face, scalp, neck, trunk 2) sub cutaneous mucinous nodules in periarticular areas and on the face and scalp with periorbital swelling.^{1,7,5}

Papulonodular lesions were reported in all patients but periorbital edema and edema of extremities occurred in a few patients.⁵ Periorbital swelling is very important to distinguish the type of localized mucinosis because it is present only in this variant of mucinosis and other types of mucinosis do not have any association with periorbital swelling.⁵

Systemic symptoms such as fever, arthralgia and muscle tenderness may be accompanied the cutaneous lesions, but paraproteinemia, bone marrow plasmocytosis and thyroid dysfunction do not always observed.¹ Etiology and pathogenesis of mucinosis is unknown⁶, but it is hypothesized

to arise from an unknown trigger that resulted in fibroblast proliferation and mucin production, this has been described as a ‘muciparous’ reaction of the connective tissue to external non-specific stimuli, chronic antigenic stimulations such as viral infections, chemotherapy, and trauma may be involved.^{1,7,8}

It is well documented that the anticonvulsant medications are one of the main culprit by which may cause dermal vessel wall inflammation. it could be speculated that in epileptic patients with gene susceptibility mucopolysaccharic acids balance (production and degeredation) may altered by chronic antigen presentation due to ingestion of toxic oil, rheumatoid arthritis, winchester syndrome and lipid proteinosis may have same clinical appearance but different metabolic deposit due to particular pathogenesis in which they share common immunologic bases of chronic antigen presentation.⁴

Table 1. Self- healing cutaneous mucinosis cases in adults since 1983 with their associations

Author/year	Age/year	Sex	Clinical features	Histopathological features	Resoloution	Association
Suhonen R et al ¹¹ , 1983	57	Man	Asymptomatic vesicle –like firm nodules on palm-wide area in his right leg and several indurated plaques of dark hue	dermal tissue was filled with mucous material which stained strongly with alcian blue and colloidal iron stains and toluidine blue	2 month	Diabetes mellitus
Cannata G et al ¹² , 1993	54	woman	A lesion on the dorsum of the right hand	mucin deposition in the reticular dermis	1 year	-----
De las heras ME et al ¹³ , 1995	26	woman	Abruptly with a papular eruption ,involving the scalp ,face, neck and trunk accompanied by peri auricular papules on the hands and arthralgies	mucin deposition in the mid dermis	Few month	-----
Jang KA et al ⁶ , 2000	34	woman	Several erythematous tender papules or nodules on both hands especially the periarticular regions.	normal epidermis, mucin deposition in the dermis	A week	-----
Brian R et al ⁷ , 2004	59	woman	6 month history of dramatic papular eruption on her face and neck	increased dermal mucin with associated plump fibroblasts, consistent with a diagnosis of papular mucinosis	2 year	-----
Yokoyama E et al ¹⁰ , 2006	70	woman	Reddish ,rice kernel-sized papules of a few days duration on her right arm	well circumscribed mucinosis stroma surrounded by dermal fibroblast like cells in the middle of dermis	2.5 month	Rheumatoid arthritis

In our patient, a preceding epileptic condition, episodes of seizures and taking an anticonvulsant drug might be considered as the underlying factors for chronic antigenic stimulation.

Clinical differential diagnosis of self-healing cutaneous mucinosis include mucinosis due to ingestion of toxic oils (toxic oil syndrome)¹⁰, lipoid proteinosis and rheumatoid arthritis. The most important differential diagnosis in children is proliferative fasciitis which presents an acute asymptomatic onset of subcutaneous firm nodules in 1-5 cm diameter on the extremities and a history of trauma.⁴

The clinical manifestation of SHCM and histopathological signs such as mucin deposition in papillary and reticular dermis and presence of gangliocyte-like giant cells within the myxoid stroma help to distinguish SHCM from proliferative fasciitis and other types of paniculitis.¹¹

Sudden onset and rapid spontaneous resolution over a period of a few weeks to several months of the skin lesions are the characteristics of SHCM lesion.⁴ It is usually limited to the skin, with good prognosis in adult type despite the poor response to any treatment. There are few cases of SHCM, and it is important for dermatologists to consider this possibility. Although SHCM may cause disfigurement, this variant is characterized by its absence of mucinosis related systemic involvement such as paraproteinemia and hypothyroidia and spontaneous resolution without any complications.

In general SHCM does not have any systemic manifestation but patients of lichen scleromyxedema may have a number of extra cutaneous manifestations pertaining to cardiovascular, pulmonary, gastrointestinal, rheumatologic, and central nervous system (CNS). Here our case presented the CNS manifestation.¹²

CONCLUSION

According to clinical finding in this patient, self-healing cutaneous mucinosis may present preorbital edema in the setting of clinical manifestation that could be considered as a differential diagnosis for angioedema and no treatment is required in such cases.

REFERENCES

1. Franco R, Alfredo R. Updated classification of papular mucinosis, lichen myxedematosus, and scleromyxedema. *J Am Acad Dermatol*. 2001;44:273-81.
2. Usha V, Yogirajan K, Papali C, Remadevi AV. Self-healing juvenile cutaneous mucinosis. *Indian J Dermatol Venereal Leprol*. 1996;62:392-3.
3. Montgomery H, Underwood L J. Lichenmyx edematosus (differentiation from cutaneous myxedemas or mucoid states). *J Invest Dermatol*. 1993;20:213-36.
4. Lavany V, Nagara J, William F, et al. Self-healing juvenile cutaneous mucinosis: cases high lighting sub cutaneous/facial involvement. *J Am Acad Dermatol*. 2006;55:1036-43.
5. Ruggero C, Carlo G. Self- healing juvenile cutaneous mucinosis. *Arch Dermatol*. 1995;131:459-61.
6. Jang KA, Han MH, Ghoi JH, Sun KJ, Moon KC, Koh JK. Recurrent self-healing cutaneous mucinosis in an adult. *Br J Dermatol*. 2000;143:645-90.
7. Brian R, Jullie A, William D. Self- healing juvenile mucinosis in an adult. *J Am Acad Dermatol*. 2004;50:121-30.
8. Cowen EW, Scott GA, Mercurio MG. Self-healing juvenile cutaneous mucinosis. *J Am Acad Dermatol*. 2004;50:597-100.
10. Sirka CS, Dulte B. Diet in dermatology. *Indian J Dermatol*. 2010;6:103-15.
11. Arti N, Mohamed K, Humoud Al-sabah, Vivek S, Kusum K. Self-healing cutaneous mucinosis manifesting with subcutaneous nodules. *Indian J Dermatol Venereal Leprol*. 2001;16:198-9.
12. Vandana Mehta, C Balachandran, Raghavendra Rao. Arndt Gottron scleromyxedema: successful response to treatment with steroid minipulse and methotrexate. *Indian J Dermatol*. 2009;54:193-5.