

The Role of Incentive Spirometry in Primary Spontaneous Pneumothorax

Rabbinu R. Pribadi, Gurmeet Singh, Cleopas M. Rumende

Department of Internal Medicine, Faculty of Medicine Universitas Indonesia - Cipto Mangunkusumo Hospital, Jakarta, Indonesia.

Correspondence mail:

Cleopas M. Rumende, MD., PhD. Division of Respiriology and Critical Illness, Department of Internal Medicine Universitas Indonesia - Cipto Mangunkusumo Hospital. Jl. Diponegoro 71, Jakarta 10430, Indonesia. email: rabbinurangga@yahoo.com.

ABSTRAK

Pneumotoraks merupakan suatu keadaan terdapatnya udara di rongga pleura. Manajemen terapi terdiri dari tatalaksana noninvasif dan invasif. Terapi ditentukan berdasarkan manifestasi klinis, serta jenis dan ukuran pneumotoraks. Berikut kami laporkan kasus seorang pasien pneumotoraks spontan primer yang ditatalaksana dengan spirometri insentif (terapi noninvasif). Seorang pria berusia 20 tahun datang ke poliklinik respirologi dengan keluhan utama sesak napas. Pasien telah didiagnosis pneumotoraks kiri berdasarkan foto rontgen dada sebelumnya dan disarankan untuk dipasang selang dada namun pasien menolak. Pada pemeriksaan didapatkan tanda vital dalam batas normal. Hasil foto rontgen dada ulang terbaru didapatkan pneumotoraks kiri seluas 33% atau 1,2 cm. Pasien diminta melakukan terapi spirometri insentif selama di rumah. Selama rentang waktu 12 hari sejak diterapi dengan spirometri, sesak napas perlahan menghilang dan pada foto rontgen dada ulangan didapatkan pneumotoraks minimal di hemitoraks kiri atas. Terapi noninvasif seperti spirometri insentif dapat dipertimbangkan pada pasien dengan keluhan minimal dan tanpa tanda distres pernapasan yang mengancam nyawa.

Kata kunci: spirometri insentif, pneumotoraks spontan primer.

ABSTRACT

Pneumothorax is the presence of air in the pleural space. Its management consists of noninvasive and invasive therapies and it is determined based on clinical manifestations, type and size of pneumothorax. We present a case of a patient with diagnosis of primary spontaneous pneumothorax treated with incentive spirometry (noninvasive therapy). A 20 year old man came to respirology clinic with chief complaint of shortness of breath. He was recently diagnosed with left pneumothorax based on previous chest X-ray in another health care facilities and was advised to undergo tube thoracostomy but he refused the procedure. On physical examination, vital signs were normal. Chest X-ray showed 33% of pneumothorax or 1.2 cm. He was asked to perform incentive spirometry therapy at home. During 12 days of therapy, shortness of breath slowly disappeared and on repeated chest X-ray, it showed minimal pneumothorax in the left upper hemithorax. Noninvasive treatment such as incentive spirometry can be considered in patient with minimal symptoms and no signs of life-threatening respiratory distress.

Keywords: incentive spirometry, primary spontaneous pneumothorax.

INTRODUCTION

Pneumothorax is defined as “the presence of gas in the pleural space”.^{1,2} Classification of pneumothorax is spontaneous (primary or secondary), traumatic, and iatrogenic pneumothorax.³⁻⁵ Primary spontaneous pneumothorax (PSP) occurs in patients without underlying pulmonary disease, no history of chest trauma, and no history of invasive medical procedures involving the chest.⁶ Primary spontaneous pneumothorax does not correlate with physical activity.⁷ The occurrence of PSP in Stockholm (Sweden) was 18 per 100,000 men per year and 6 per 100,000 women per year between 1975 and 1984.³ Tall and lean 10-30 year old males are prone to have PSP.⁴ Smoking is also a risk factor of PSP in males.^{4,5}

Diagnosis of PSP consists of history taking, physical examination and confirmed by radiology examination such as chest X-rays.^{2,7,8} The management of PSP is determined primarily by clinical manifestations, and less importantly the type and size of pneumothorax.^{7,8} The available treatments are noninvasive (conservative) and invasive therapies.⁹⁻¹⁰

Primary spontaneous pneumothorax which resolved with conservative therapy is quite rare to find in our daily clinical practice. Therefore we present a case of a male patient who was diagnosed PSP and treated with incentive spirometry.

CASE ILLUSTRATION

A 20 year old man came to respirology clinic with chief complaint of shortness of breath since 4 weeks. Shortness of breath was sudden as he woke up in the morning. He denied fever, cough, bloody cough, chest pain on inspiration, history of chest trauma, palpitations, swollen legs, or history of invasive medical procedures involving the chest. Five days later, the patient went to a clinic & chest X-ray was done. The result of the chest X-ray showed left pneumothorax. He was advised to undergo tube thoracostomy but he refused. Sixteen days later he went to the local hospital and chest X-Ray was done for second time. It showed an improvement of left pneumothorax but the size was still large enough. Tube thoracostomy was still advised but he

refused the procedure. One month later, he came to our respirology clinic. At that time, shortness of breath had decreased. He denied any history of tuberculosis and lung diseases. Patient did not have history of smoking.

On physical examination respiratory rate was 20 times per minute and other vital signs were normal. His body mass index was 18.1 kg/m². Lung examination revealed decreased tactile fremitus on left hemithorax, hyperresonant percussion on left hemithorax, and decreased vesicular sounds on left hemithorax. Examination of other organs was within normal limits. First chest X-ray showed 80% left pneumothorax according to British Thoracic Society (BTS) old method. Based on BTS 2003, the size of pneumothorax was 5 cm and according to American College of Chest Physician (ACCP) 2001, the size of the pneumothorax was 11 cm.

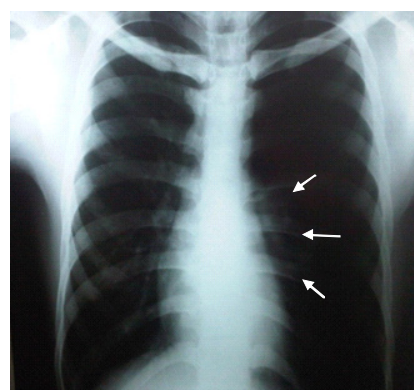


Figure 1. First Chest X-Ray (arrows pointing pleural line)

The second chest X-ray, which was done 11 days later showed 62 % left pneumothorax (BTS old method). According to BTS 2003 the size of left pneumothorax was 2.5 cm and based on ACCP 2001 the size of pneumothorax.

The third chest X-ray, which was done at our hospital 12 days after the second chest X-ray showed 33 % left pneumothorax (BTS old method). According to BTS 2003 the size of left pneumothorax was 1.2 cm and based on ACCP 2001 the size of pneumothorax was 3.5 cm.

Clinically the patient did not experience any respiratory distress. He was asked to perform incentive spirometry 2-4 times a day with the duration of 5-10 minutes at home. We advise him to gradually increased the volume of spirometry based on patient’s capability.

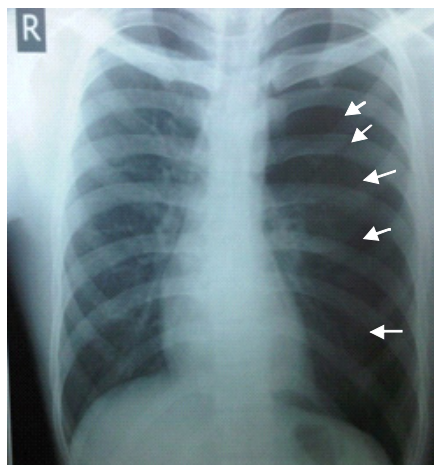


Figure 2. Second chest X-ray (arrows pointing pleural line)

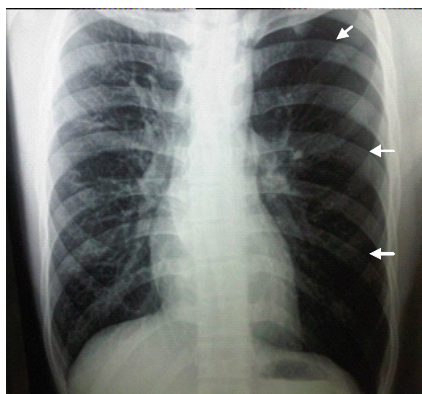

Figure 3. Third chest X-ray (arrows pointing pleural line)

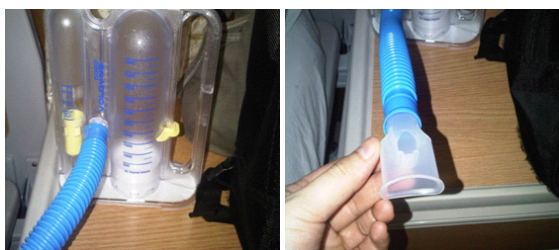

Figure 4. Incentive spirometry

Within twelve days after patient initiated incentive spirometry therapy, shortness of breath slowly disappeared. The fourth chest X-ray was done. According to BTS old method, it showed 0 %, and based on BTS 2003 the size was 0 cm. According to ACCP 2001, the size of left pneumothorax was 1 cm.

DISCUSSION

Primary spontaneous pneumothorax is diagnosed based on sudden shortness of breath or

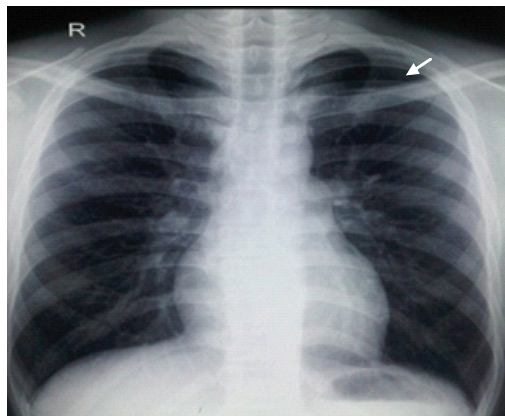


Figure 5. Fourth chest X-ray (arrow pointing pleural line)

pleuritic chest pain, the history of no underlying pulmonary disease, no chest trauma, no invasive medical procedures involving the chest, lung examination consistent with pneumothorax, and appearance of pleural line and hyperlucent hemithorax on chest X-ray. It has no association with physical activity.^{2,7} Predisposition factors are tall, lean, male, young (10-30 year old), and smoking history.^{4,5} Predisposition factors in this patient were lean (body mass index 18.1 kg/m²), male sex and young age (20 year old).

Based on BTS guidelines for the management of spontaneous pneumothorax 2010, conservative therapy is therapy of choice if the patient has minimal symptoms.⁷ He came without any symptoms and signs of respiratory distress. The chest X-ray at our hospital showed the size of the left pneumothorax was 1.2 cm (BTS 2003 method) or 33% (BTS old method). We decided to treat this patient with noninvasive therapy such as incentive spirometry.

The role of incentive spirometry as a therapy for PSP is not well documented. There are not many literatures that describes incentive spirometry benefits for PSP management. Latest guideline from BTS 2010 defines conservative management as an observation only without mentioning spirometry.⁷ Mechanism of spirometry is to sustain maximal inspiration to increase the absorption of air in the pleural space.¹¹ This patient had come a long way from previous health care facilities and instead of only observation, we provided him with incentive spirometry to accelerate the resolution of the PSP.

Based on the literature, the gas in the pleural

cavity will be absorbed naturally 1.25% per day.¹² Without intervention, gas in pleural space of this patient will be absorbed 15% in 12 days and will be completely absorbed in 26 days. In a span of 12 days after treatment with incentive spirometry, his conditions improved and the size of pneumothorax decreased from 33% to minimal pneumothorax in this patient. Potential role of incentive spirometry should be studied further to establish its usefulness in PSP patients.

CONCLUSION

Management of primary spontaneous pneumothorax should be done based on combination of patient's clinical manifestation and radiological presentation. Incentive spirometry can be considered in PSP patients with minimal symptoms and no signs of life-threatening respiratory distress.

REFERENCES

1. Light RW. Disorders of the pleura and mediastinum. In: Fauci AS, Braunwald E, Kasper DL, et al, eds. *Harrison's principles of internal medicine*. 17th ed. New York: McGraw Hill; 2008. p.1660.
2. Hisyam B, Budiono E. Pneumotoraks. In: Setiati S, Alwi I, Sudoyo AW, et al, eds. *Buku ajar ilmu penyakit dalam*. 6th ed. Jakarta: Interna Publishing; 2014. p. 1640-50.
3. Tschopp JM, Bintcliffe O, Astoul P, et al. ERS task force statement: diagnosis and treatment of primary spontaneous pneumothorax. *Eur Respir J*. 2015;46: 321-35.
4. Sahn SA, Heffner JE. Spontaneous pneumothorax. *N Engl J Med*. 2000;342(12):868-74.
5. Idrees MM, Ingleby AM, Wali SO. Evaluation and management of pneumothorax. *Saudi Med J*. 2003; 24(5):447-52.
6. Baumann MH, Strange C, Heffner JE, et al. Management of spontaneous pneumothorax: an American College of Chest Physicians delphi consensus statement. *Chest*. 2001;119:590-602.
7. MacDuff A, Arnold A, Harvey J. Management of spontaneous pneumothorax: British Thoracic Society pleural disease guidelines 2010. *Thorax*. 2010; 65(Suppl 2):ii18-ii22.
8. Ismail T, Anshar MF, How SH, Hashim CWA, Mohamad WHW, Katiman D. A survey on the initial management of spontaneous pneumothorax. *Med J Malaysia*. 2010;65(3):180-3.
9. Henry M, Arnold T, Harvey J. BTS guidelines for the management of spontaneous pneumothorax. *Thorax*. 2003;58(Suppl II):ii39-ii42.
10. Kelly AM. Treatment of primary spontaneous pneumothorax. *Curr Opin Pulmon Med*. 2009;15: 376-9.
11. Trauma Center of the Rockies. Pneumothorax/Hemothorax. 2012 [cited August 5th 2012]. Available from <http://pvhs.org/.../pneumothoraxhemothorax.pdf>
12. Daley BJ, Bhimji S, Bascom R, et al. Pneumothorax. 2012 [cited August 5th 2012]. Available from <http://emedicine.medscape.com/article/4245-overview>.