

Graves' Dermopathy: Responsive with Intralesion Steroid

Tri Juli E. Tarigan¹, Rahadi Rihatmadja², Erna Hutabarat³

¹ Department of Internal Medicine, Faculty of Medicine, Universitas Indonesia - Cipto Mangunkusumo Hospital, Jakarta, Indonesia.

² Department of Dermato Venereology, Faculty of Medicine, Universitas Indonesia - Cipto Mangunkusumo Hospital, Jakarta, Indonesia.

³ Department of Dermato Venereology, PELNI Hospital, Jakarta, Indonesia.

Correspondence mail:

Division of Endocrinology and Metabolism, Department of Internal Medicine, Faculty of Medicine Universitas Indonesia - Cipto Mangunkusumo Hospital. Jl. Diponegoro no. 71, Jakarta 10430, Indonesia.

email: tje_tar@yahoo.com.

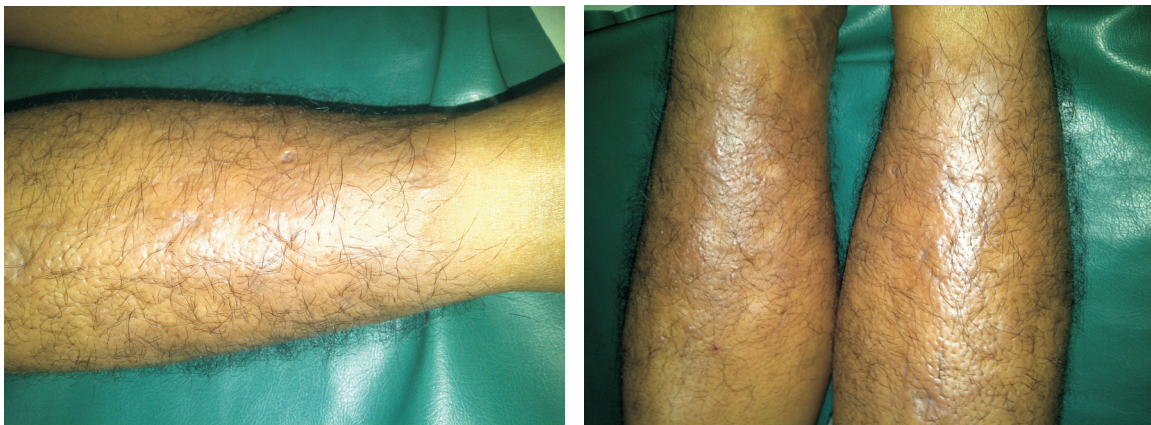


Figure 1. Before being given corticosteroid injection intralesion

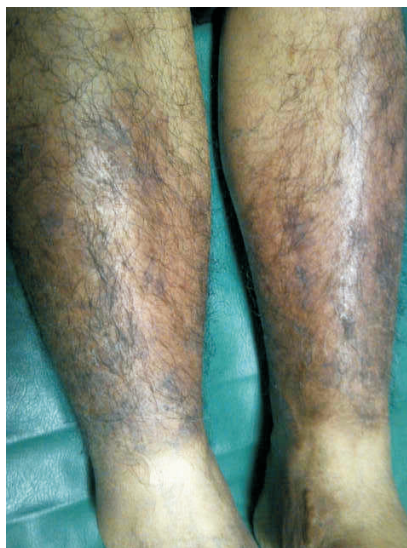

Figure 2. After being given treatment

Table 1. Laboratory examination

	14/02/12	17/02/12	03/04/12	18/06/12	14/08/12	30/07/13	17/12/13
FT4 (ng/dL)	1.30		0.61	0.71	1.91	2.35	0.63
TSHs(μ IU/mL)	0.008			12.285	0.011	<0.004	15.940
T3 (ng/mL)	1.52		1.30				
TRAb(IU/L)		>40.0		12.7			

A 51-year-old male came with thickening lesion in both legs since 2.5 years before presented. It started with small lesion and went larger. Before diagnosed, he was admitted to hospital due to unresolved headache. He complained nausea, easily hungry, protrusion of both eyes without diplopia or diminution of vision, tremor, palpitation, and unintentional weight loss (25-30 kgs in a year).

On examination, it was found that he was in thyrotoxic condition and has diffuse goiter. From skin examination he had raised hyperkeratotic, and waxy plaque like lesions over both pretibial region.

Laboratory examination confirm for thyrotoxic with presumably Graves' disease with the result on **Table 1**.

Thyroid scintigraphy showed diffused enlargement and increased uptake. Skin biopsy from the pretibial skin showed epidermis with vacuolar degeneration, partly spongiotic and hyperpigmented, thickening basalis membrane, miksoid dermis and spreading chronic inflammatory cell in perivascular and periadneksal. It confirmed the diagnosis of myxedema hystologically.

The patient was given methimazole with starting dose 3x10 mg and propranolol 2x10 mg. Methimazole was reduce according to lab result. The pretibial lesion was given Triamcinolone acetonide injection intralesion in both legs with starting dose 0.5 cc (preparation 10 mg/cc) per day and increased according to response. The patient was response to 1.5 cc per leg per day. The patient also given Kloderma Ointment used twice a day. The lesion now thinning, flat, and turn hyperpigmentation as can be seen in figures.