

## Gastrointestinal Presentation in COVID-19 in Indonesia: A Case Report

**Muhammad K. Azwar<sup>1</sup>, Fauzia Kirana<sup>2</sup>, Adi Kurniawan<sup>2</sup>, Sri Handayani<sup>2</sup>, Siti Setiati<sup>3</sup>**

<sup>1</sup> Faculty of Medicine, Universitas Indonesia, Jakarta, Indonesia

<sup>2</sup> Permata Jonggol Hospital, Bogor, Indonesia

<sup>3</sup> Department of Internal Medicine – Clinical Epidemiology and Evidence-Based Medicine, Cipto Mangunkusumo Hospital – Faculty of Medicine Universitas Indonesia, Jakarta, Indonesia

### Corresponding Author:

Prof. Siti Setiati, MD., PhD. Department of Internal Medicine – Clinical Epidemiology and Evidence-Based Medicine, Cipto Mangunkusumo Hospital – Faculty of Medicine Universitas Indonesia. Jl. Diponegoro No. 71, 10430 Jakarta, Indonesia. email: s\_setiati@yahoo.com.

### ABSTRAK

*Severe acute respiratory syndrome coronavirus 2 (SARS-CoV-2) telah menyebabkan infeksi yang tersebar ke seluruh penjuru dunia. Selama pandemi, dokter perlu mencurigai pasien berisiko dengan gejala saluran pencernaan secara dini. Gejala tersebut memang tidak umum ditemukan pada pasien infeksi virus corona 2019 (COVID-19). Laporan kasus ini menjelaskan seorang pasien di Indonesia yang datang dengan keluhan nyeri dada dan gejala saluran pencernaan. Pasien terkonfirmasi positif setelah menjalani rawat inap beberapa hari di bangsal umum.*

**Kata kunci:** COVID-19, SARS-CoV-2, nyeri perut, gejala saluran pencernaan, Indonesia.

### ABSTRACT

*Severe acute respiratory syndrome coronavirus 2 (SARS-CoV-2) is currently causing a widespread infection in the world. During the pandemic, physicians may need to raise the index of suspicion earlier in at-risk patients presenting with gastrointestinal symptoms, which are uncommon findings in coronavirus disease 2019 (COVID-19) patients. We report a patient in Indonesia with chest pain and gastrointestinal symptoms who was later confirmed to have SARS-CoV-2 infection after spending days of hospitalisation in the standard ward.*

**Keywords:** COVID-19, SARS-CoV-2, abdominal pain, gastrointestinal symptom, Indonesia.

### INTRODUCTION

Severe acute respiratory syndrome coronavirus 2 (SARS-CoV-2) is currently causing a widespread infection in the world.<sup>1</sup> Physicians may need to raise the index of suspicion earlier in at-risk patients presenting with gastrointestinal symptoms,<sup>2</sup> which are uncommon findings in COVID-19 patients. Some patients may complain of abdominal pain, vomiting and diarrhoea,

instead of respiratory symptoms.<sup>1</sup>

We describe a patient in Indonesia with chest pain and gastrointestinal symptoms who was later confirmed to have SARS-CoV-2 infection in this case report.

### CASE ILLUSTRATION

A 23-year-old lady came to the A&E in Bogor, Indonesia during COVID-19 pandemic

with chest pain, epigastric pain and shortness of breath since 4.5 hours before admission. The sales promotion employee presented with retrosternal chest pain radiating to the epigastrium. The pain was felt intermittently whilst doing physical activity or taking a rest, accompanied by breathing difficulty. Pain resolved itself without medication or the need to take a rest. She denied painful swallowing. The patient admitted eating spicy and oily food frequently. She also had nausea and vomiting.

Since 2 days before admission, she had experienced occasional dry cough and fever. Pain was felt in all joints in the body. Retroorbital pain, headache, and skin rash were absent. She had no problem with passing urine and bowel movement. Past medical history and drug history were unremarkable, with no past episodes of GERD symptoms. She was a nonsmoker whose father and mother remained healthy. On the day of her hospital admission, there had been no reported local transmission of COVID-19 in her residential area. There were no known COVID-19 contact and travel history.

At the time of examination, she was alert. Temperature was 37.9°C, pulse 125 bpm, respiratory rate 30 times/min, and pulse oximeter 88% saturation without supplemental oxygen. Conjunctiva was pale. The chest was clear bilaterally and the pain was not reproduced by palpation. Bowel sound was normal. Abdomen was soft and nontender without liver enlargement. The remainder of the physical examination was normal.

Initial investigation showed normocytic anaemia (haemoglobin 10.1 g/dL, mean corpuscular volume 85 fL, mean corpuscular haemoglobin 26 pg, mean corpuscular haemoglobin concentration 31%), haematocrit 33%, normal white cell count (7,000/mcL), and thrombocytopenia (116,000/mcL).

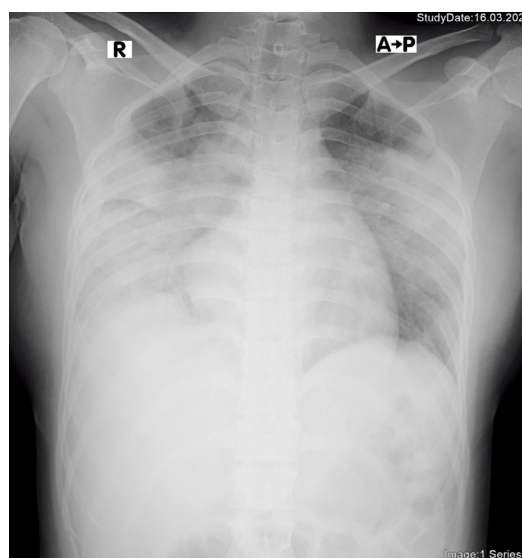
Differential diagnoses of this patient were gastroesophageal reflux disease, dengue fever, and idiopathic bicytopenia. Initial treatment were intravenous fluid with lactated Ringer's solution. Other treatment plans were as follows:

- Oxygen supplementation 3 L/min
- Omeprazole 40 mg i.v. o.d.
- Ondansetron 4 mg i.v. t.i.d.

- Sucralfate suspension 10 ml p.o. t.i.d.
- N-acetylcysteine 200 mg p.o. t.i.d.
- Curcuma xanthorrhiza extract tablet 20 mg p.o. o.d.

### Outcome and Follow Up

The patient was transferred to the standard ward for further evaluation and treatment. On the second day of inpatient treatment, she complained of shortness of breath whilst on room air, still accompanied by epigastric pain. Respiratory rate was 21 times/min and other vital signs were unremarkable. There were reduced breath sounds bilaterally and epigastric tenderness. She also developed pancytopenia. Chest x-ray revealed increased vascular marking, blunted right costophrenic angle and bilateral peripheral opacities suggestive of pneumonia. (**Figure 1**) Serum electrolytes were within normal limit. It is suspected that the patient had community acquired pneumonia (CAP) and systemic lupus erythematosus (SLE). Thus, physician started additional administration of ceftriaxone 1 g i.v. o.d. and methylprednisolone 4 mg p.o. t.i.d.



**Figure 1.** Chest x-ray of illness day 4, hospital day 2.

On the third day of inpatient treatment, she still complained of difficulty breathing despite oxygen supplementation, tiredness, slight nausea and dry cough, whereas abdominal pain resolved. Vital signs were within normal limit. There was elevated erythrocyte sedimentation rate (ESR)

(112 mm/h) and concurrent bicytopenia. Due to the suspicion that she had concomitant GERD and SARS-CoV-2 infection, she was moved to the isolation ward. Methylprednisolone p.o. was changed to 62.5 mg i.v. b.i.d. Third-generation cephalosporin administration was still continued (day 2).

On the first day in the isolation ward (day 4 of treatment), there was improvement of breathing and nausea. The patient was in Fowler position complaining of tiredness and her difficulty expelling phlegm. She was afebrile and her respiratory rate was 28 times /min. Pulse oximeter showed 97% saturation. Liver function tests were abnormal (aspartat aminotransferase 38 U/L and alanine aminotransferase 32 U/L). Antibiotic was changed to Levofloxacin 500 mg i.v. o.d., whereas methylprednisolone and curcuma extract administration were discontinued. Physician started additional multivitamin i.v. and folic acid p.o. o.d. Chloroquine and oseltamivir were not available in the hospital.

On the second day in the isolation ward (day 5 of treatment), nasopharyngeal swab was taken for reverse transcription polymerase chain reaction (RT-PCR) SARS-CoV-2. Patient only complained of fatigue. Blood pressure was 90/70 mm Hg, respiratory rate 24 times/min, temperature 36.4°C, and pulse oximeter 95% saturation on 3 L/min oxygen. Physician added lactulose 5 ml p.o. t.i.d to the existing care plan because of no bowel movement for 3 consecutive days.

On the third day in the isolation ward (day 6 of treatment), her complaint was only intermittent dry cough. Patient received the same treatment as the previous day. Oxygen supplementation was discontinued following oxygen saturation result being 96%. Test results showed anaemia (hemoglobin 10 g/dL), severe leucopenia (1,900 /mcL), and normal platelet count (193,000 /mcL). There were neutropenia and lymphocytosis. Differential count also revealed lower percentage of eosinophil, normal percentage of basophil, and higher percentage of monocyte. On the fourth and fifth day in the isolation ward, the patient still complained of absent bowel movement and received usual treatment. Vital signs were within normal limit without oxygen supplementation.

On the following day, she finally had her first bowel movement. Test results still showed anaemia, leucopenia, and neutropenia, but normal lymphocyte percentage. ESR was 100 mm/h. After 5 days of wait, RT-PCR revealed that the patient had SARS-CoV-2 infection. Afterwards, she was referred to one of the COVID-19 referral centres.

## DISCUSSION

This patient came to the A&E with the most common symptoms of COVID-19, including shortness of breath, fatigue, dry cough, myalgia and fever.<sup>3</sup> The chief complaints included chest pain and epigastric pain. Chest pain is present in several COVID-19 patients irrespective of the pregnancy status.<sup>4</sup>

Gastrointestinal symptoms in this patient were epigastric pain and vomiting. Physicians may need to raise the index of suspicion early in at-risk patients presenting with gastrointestinal symptoms,<sup>2</sup> although those are uncommon in COVID-19 patients. According to a multicentre descriptive study in China, abdominal pain in general and vomiting occurred only in 2% and 3.9% of COVID-19 patients, respectively. Unfortunately, the time from disease onset to hospital admission is prolonged significantly in COVID-19 patients with digestive symptoms (9.0 days vs 7.3 days) compared to those without digestive symptoms.<sup>2</sup>

SARS-CoV-2 viral entry into human cells depends on specific cell receptor (angiotensin-converting enzyme II [ACE-2]) and host cellular transmembrane serine protease (TMPRSS). ACE-2-expressing cells in human include lung alveolar type 2 cells, upper and stratified epithelial cells in oesophagus, and absorptive enterocytes in ileum and colon.<sup>5</sup> Studies have also identified the SARS-CoV-2 RNA in stool specimens of infected patients.<sup>1</sup> Once enterocyte is infected, there will be an increased wall permeability to foreign pathogens<sup>5</sup> and viral replication in the gastrointestinal lining cells.<sup>1</sup> The invasion of enterocyte will in turn cause malabsorption, leading to enteric symptom.<sup>5</sup> Diarrhoea can be the onset symptom in COVID-19 patient, without cough, fever, dyspnoea or chest pain.<sup>6</sup>

This case is a 23-year-old woman with no

relevant past travel, medical or contact history. However, as a sales promotion employee, this patient has frequent close contact with people. Any job that requires human-to-human contact frequently, regardless of the COVID-19 status, is considered having medium exposure risk.<sup>7</sup> The median incubation period was estimated to be 5.1 days (95% Confidence interval [CI] 4.5 to 5.8 days).<sup>8</sup> Although the swab was taken on the fifth day of hospitalisation, this case was less likely to be intra-hospital infection of COVID-19.

Initial workup resulted in several differential diagnoses, including GERD and dengue fever. Infectious oesophagitis may be associated with GERD presenting with retrosternal pain, fever, and dysphagia.<sup>9</sup> However, this case report patient did not complain about odynophagia, which is a predominant feature in oesophagitis. After days of treatment, GERD became less likely to be the only culprit.

Clinical and laboratory features of COVID-19 and dengue are difficult to distinguish.<sup>8</sup> The patient had an acute fever in Indonesia, where dengue is endemic, accompanied by nausea and vomiting, abdominal pain, arthralgia, low platelet count, but without concurrent increase in haematocrit. The treatment of this probable dengue case warranted inpatient admission for strict observation in part due to a warning sign, namely abdominal pain. If rapid test for non-structural protein NS1 had been done in this case, a positive dengue result should not have made physicians fail to consider COVID-19. Nevertheless, there have been reported cases of false-positive dengue results in patients with COVID-19.<sup>10</sup>

Chest x-ray of this patient revealed increased vascular marking, blunted costophrenic angle and bilateral peripheral opacities. The most discriminating features for pneumonia in COVID-19 patients compared to non-COVID-19 pneumonia included a peripheral distribution (80% vs. 57%), vascular thickening (58% vs. 22%) and ground-glass opacity (91% vs. 68%).<sup>11</sup> Abnormality around the costophrenic angle may signify pleural effusion. However, pleural effusion, pericardial effusion, and pneumothorax, are uncommon findings in COVID-19 patients. As physicians monitor cases of COVID-19

pneumonia using radiographic imaging, there will be lower number of lesions and involved lobes as clinical improvement occurs. In addition, imaging patterns pertinent to the improvement also include gradual resolution of consolidative opacities.<sup>12</sup> Chest X-ray is, however, less sensitive compared to CT scan.<sup>13</sup>

ESR laboratory trends were done for this patient, because physician should aim to screen for hyperinflammation.<sup>14</sup> ESR is still routinely used to assess inflammation.<sup>15</sup> Up to 85% of patients hospitalised for COVID-19 had increase in ESR.<sup>16</sup> A subgroup of patients with severe COVID-19 was shown to have cytokine storm syndrome.<sup>14</sup> Nevertheless, there is an increase in ESR in the case of renal pathology, older age, and female sex.<sup>15</sup>

Prior to the confirmatory diagnosis, this patient showed normal leucocyte, but with thrombocytopenia and anaemia. Leucopenia developed on the fifth day after the onset of cough and fever. The patient also had neutropenia, normal to high lymphocyte percentage and lower percentage of eosinophils. Anaemia was found in 41-50% of patients with COVID-19.<sup>16</sup> Severe cases of COVID-19 tend to have higher leucocyte count, lower lymphocyte count, and lower percentage of basophil, eosinophil and monocyte.<sup>3</sup>

The tropism of SARS-CoV-2 to the gastrointestinal tract and involvement of gastrointestinal tract have important implications to both patient management and infection control. Following aerosol-generating activity, faeces is a potential source of virus. Toilet fume contributed to the major outbreak during the SARS epidemic in Hong Kong. This may highlight the importance of preparedness in terms of personal protective equipment, for instance in the endoscopy setting.<sup>1</sup>

The limited hospital resources and delayed diagnosis may bring about the rapid spread of COVID-19.<sup>17</sup> The initial treatment of this patient in the standard ward may cause spread to patients and healthcare workers unaware of the risk of transmission of SARS-CoV-2. More drastic measures are needed to lower the risk of disease transmission significantly, including shortening the period from symptom onset to isolation of



patients. Improvement in timely diagnosis and shortening of waiting time can significantly lower the risk of disease transmission.<sup>17</sup>

## CONCLUSION

During the COVID-19 pandemic, physicians may need to raise the index of suspicion earlier in at-risk patients presenting with gastrointestinal symptoms, including vomiting and abdominal pain. As several patients infected by SARS-CoV-2 are not able to recall a clear history of a known exposure, it is important to include occupational history in history taking. Failure to have a confirmed COVID-19 diagnosis early may cause inappropriate and unnecessary intervention. Improvement in timely diagnosis and shortening of waiting time are needed to decrease the risk of disease transmission significantly.

## ACKNOWLEDGMENTS

We thank Permata Jonggol hospital staffs for their efforts to deal with COVID-19. We also thank the Almighty God for reasons too numerous to mention. We declare no competing interests.

## REFERENCES

1. Wong SH, Lui RNS, Sung JJY. Covid-19 and the digestive system. *J Gastroenterol Hepatol*. 2020;25:13. <https://doi.org/10.1111/jgh.15047>.
2. Pan L, Mu M, Yang P, et al. Clinical characteristics of COVID-19 patients with digestive symptoms in Hubei, China: a descriptive, cross-sectional, multicenter study. *Am J Gastroenterol*. 2020;25. [https://journals.lww.com/ajg/Documents/COVID\\_Digestive\\_Symptoms\\_AJG\\_Preproof.pdf](https://journals.lww.com/ajg/Documents/COVID_Digestive_Symptoms_AJG_Preproof.pdf).
3. Qin C, Zhou L, Hu Z, et al. Dysregulation of immune response in patients with COVID-19 in Wuhan, China. *Clin Infect Dis*. 2020 Mar 12; pii: ciaa248. doi: 10.1093/cid/ciaa248.
4. Panahi L, Amiri M, Pouy S. Risks of Novel Coronavirus Disease (COVID-19) in Pregnancy; a Narrative Review. *Arch Acad Emerg Med*. 2020;8(1):e34.
5. Gu J, Han B, Wang J. COVID-19: Gastrointestinal Manifestations and Potential Fecal–Oral Transmission. *Gastroenterology*. 2020 Mar 3; pii: S0016-5085(20)30281-X. doi: 10.1053/j.gastro.2020.02.054.
6. Song Y, Liu P, Shi XL, et al. SARS-CoV-2 induced diarrhoea as onset symptom in patient with COVID-19. *Gut*. 2020 Mar 5; pii: gutjnl-2020-320891. doi: 10.1136/gutjnl-2020-320891.
7. Occupational Safety and Health Administration. Worker Exposure Risk to COVID-19. USA: Occupational Safety and Health Administration; 2020. <https://www.osha.gov/Publications/OSHA3993.pdf>
8. Lauer SA, Grantz KH, Bi Q, et al. The Incubation Period of Coronavirus Disease 2019 (COVID-19) From Publicly Reported Confirmed Cases: Estimation and Application. *Ann Intern Med*. 2020 Mar 10. doi: 10.7326/M20-0504.
9. Grossi L, Ciccaglione AF, Marzio L. Esophagitis and its causes: Who is “guilty” when acid is found “not guilty”? *World J Gastroenterol*. 2017;23(17): 3011–6. doi: 10.3748/wjg.v23.i17.3011.
10. Yan G, Lee CK, Lam LTM, et al. Covert COVID-19 and false-positive dengue serology in Singapore. *Lancet Infect Dis*. 2020 Mar 4; pii: S1473-3099(20)30158-4. doi: 10.1016/S1473-3099(20)30158-4.
11. Bai HX, Hsieh B, Xiong Z, et al. Performance of radiologists in differentiating COVID-19 from viral pneumonia on chest CT. *Radiology*. 2020; 28. <https://doi.org/10.1148/radiol.2020200823>.
12. Salehi S, Abedi A, Balakrishnan S, et al. Coronavirus disease 2019 (COVID-19): A systematic review of imaging findings in 919 patients. *Am J Roentgenol*. 2020;215:1-7. doi: 10.2214/AJR.20.23034.
13. Susilo A, Rumende CM, Pitoyo CW, et al. Coronavirus disease 2019: Tinjauan literatur terkini. *J Penyakit Dalam Indones*. 2020;7(1):45-77.
14. Mehta P, McAuley DF, Brown M, et al. *Lancet*. 2020;2. Available from: [https://doi.org/10.1016/S0140-6736\(20\)30628-0](https://doi.org/10.1016/S0140-6736(20)30628-0).
15. Harrison M. Erythrocyte sedimentation rate and C-reactive protein. *Aust Prescr*. 2015;38(3):93–4. doi: 10.18773/austprescr.2015.034.
16. Lippi G, Plebani M. Laboratory abnormalities in patients with COVID-2019 infection. *Clin Chem Lab Med*. 2020 Mar 3; pii: /j/cclm.ahead-of-print/cclm-2020-0198/cclm-2020-0198.xml. doi: 10.1515/cclm-2020-0198.
17. Rong X, Yang L, Chu H, et al. Effect of delay in diagnosis on transmission of COVID-19. *Mathematical Biosciences and Engineering*. 2020;17(3):2725-40. doi: 10.3934/mbe.2020149.